

INFLUENCE OF PLASTIC SURGERY OF THE INFERIOR TURBINATE ON THE PATENCY OF THE EUSTACHIAN TUBE

Andrzej WOJDAS¹, Roman STABLEWSKI¹, Elżbieta ZGNILEC¹

¹ Department of Otolaryngology, Military Institute of Aviation Medicine, Warsaw, Poland

Source of support: Own sources

Author's address: A. Wojdas, Military Institute of Aviation Medicine, Krasińskiego Street 54/56, 01-755 Warsaw, e-mail: awojdas@wiml.waw.pl

Introduction: Chronic hypertrophic rhinitis is one of the most common diseases in rhinology. Various surgical techniques are used to reduce hypertrophic changes in the inferior turbinates. The aim of our study is to determine the impact of plastic surgery of the lower nasal turbinates, performed by cryoablation or radiocoblation, on the patency of the Eustachian tube and to determine how long the waiting period should be for activities that particularly require patent ear tubes, such as traveling by plane.

Material: A total of 70 patients treated at the Department of Otolaryngology of the Military Institute of Aviation Medicine were qualified for the study. Due to the technique of conchoplasty of the lower nasal turbinates, the patients were divided into two groups. Group I consisted of 35 patients, including 15 women and 20 men, aged 24 to 62 (mean 42.67 years), operated on by cryoablation. Group II also comprised 35 patients, including 12 women and 23 men, aged 29 to 69 (mean 44.21 years), operated on by radiocoblation.

Methods: Plastic surgeries of the lower nasal turbinates, also known as conchoplasties, were performed under local anesthesia with a cryosurgery machine with the use of a nasal applicator and an apparatus for submucosal coblation with the use of radio waves. The patency of the Eustachian tube was assessed by tympanometry before the operation and 1, 2 and 3 weeks after the operation.

Results: No statistically significant ($p < 0.001$) disturbances of the patency of the Eustachian tubes were observed after conchoplastic surgeries, using both the cryoablation and radiocoablation methods.

Conclusions: Conchoplasties of the lower nasal turbinates performed by cryo- and radiocoblation do not impair the patency of the Eustachian tubes. After operations on the lower nasal turbinates, the waiting period for activities that particularly require patent tubes should be two weeks.

Keywords: chronic hypertrophic rhinitis, cryoablation, obstruction of the Eustachian tube, radiocoblation

INTRODUCTION

Chronic hypertrophic rhinitis is one of the most common diseases in rhinology. Patients with hypertrophy of the nasal turbinate mucosa have impaired regulatory processes on its surface. The inferior nasal turbinate is most often affected, as it occupies the largest part of the nasal cavity. This is manifested primarily by impaired nasal patency, but also by deterioration of the sense of smell, chronic rhinitis, recurrent upper respiratory tract infections, snoring, obstructive sleep apnea, and very occasionally ear plugging, by blocking the Eustachian tube outlet [2,10,30].

In cases of failure of conservative treatment (intranasal corticosteroids, antihistamines, vasoconstrictors), patients are qualified for surgical treatment [24]. Numerous surgical procedures using cryoablation, radioablation, microneedle radiofrequency, argon plasma, diode laser or carbon dioxide laser have been described to reduce hypertrophic lesions of the inferior nasal turbinates [12,16,17,20,25,26,31,32].

Patients operated on for hypertrophic lesions of the inferior nasal turbinates usually report from the first day, apart from pain, obstruction of the nasal cavity and a feeling of “plugged ears” [7,9,10,13]. Pain most often subsides after a few hours, nasal obstruction usually resolves between 5 and 7 days after surgery, while the feeling of “plugged ears” can persist much longer [5,8,10,21,23,29].

OBJECTIVE

The objective of our study is to determine the effect of plastic surgery of the inferior nasal turbinate (conchoplasty) performed by cryoablation or radioablation, on the patency of

the Eustachian tube and to determine how long, from the performance of the operation, should be the grace period for activities that particularly require the patency of the Eustachian tube, having primarily in mind the possibility of safe airplane flying.

MATERIAL

A total of 70 patients treated at the Department of Otolaryngology of the Military Institute of Aviation Medicine for chronic hypertrophic rhinitis were eligible for the study. The following criteria were used to diagnose the disease: bilateral, alternating nasal blockage exacerbated in the horizontal position, hypertrophy of the inferior nasal turbinate mucosa on physical examination, endoscopic examination of the nasal cavity and computed tomography images. Exclusion criteria for the study were the coexistence of deviated septum, chronic sinusitis, nasal polyps, allergic rhinitis and a history of rhinologic surgery. The patients underwent bilateral plastic surgery of the lower nasal turbinates (conchoplasty). Based on the technique used to perform inferior nasal turbinate conchoplasties, patients were divided into two groups. Group I consisted of 35 patients, including 15 women and 20 men aged 24 to 62 years (mean. 42.67 years), operated by cryoablation. Group II also consisted of 35 patients, including 12 women and 23 men, aged 29 to 69 years (mean. 44.21 years), operated by radioablation. The selection of patients for the method of inferior nasal turbinate plastic surgery was random.

METHODS

Eustachian tube obstruction was assessed by tympanometry performed with an automated easyTymp impedance audiometer from Maico Diagnostic GmbH. Tympanometric examinations were performed before surgery and at 1, 2 and 3 weeks after surgery. The test determines the elasticity of the eardrum and determines the pressure in the middle ear. The susceptibility assessment was measured through a probe in the external ear canal that simultaneously emits a 226Hz pure tone. The probe also contains a microphone that records at what variable pressure applied from the probe (measuring from -300 to + 200 daPa) the eardrum reflects as little sound as possible from itself and passes it on to the middle ear. The test assesses the pressure (the peak of the tympanometric curve) in the middle ear, which in the norm should be between - 100 and + 100 daPa (type A curve). The result of the test (measurement) is a graph of static susceptibility as a function of varying pressure. If the curve

is falls below a pressure of -100 daPa (curve type C), we speak of impaired patency of the Eustachian tube, if the curve is flat (curve type B), the Eustachian tube is obstructed.

Plastic surgeries of the inferior nasal turbinates were performed under local superficial anesthesia with 10% lignocaine and under local infiltration anesthesia with 1% lignocaine with epinephrine after premedication within a one-day hospitalization. No intranasal dressings were placed after the operation.

Cryoablation of the inferior nasal turbinates was performed with the Cryo-S Classic apparatus from Metrum CryoFlex Poland using a flat L-50 applicator. The position of the tip was controlled by anterior rhinoscopy. The time for a single freezing of the mucosa of both turbinates was 60 seconds, which was repeated three times after tissue propagation.

Radioablation of the inferior nasal turbinates was performed with a Celon System instrument from Olympus USA using a ProBreath bipolar nasal electrode. The position of the tip was controlled with an endoscope with simple optics. The time of a single radioablation was from 3 to 7 seconds, with a power of 12W, which was performed submucosally every 10 mm along the entire length of the inferior nasal turbinate.

The results obtained were statistically analyzed using the Chi2 test, assuming a significance level of $p < 0.001$.

RESULTS

The obtained tympanometric results are shown in the figures (Fig. 1-4).

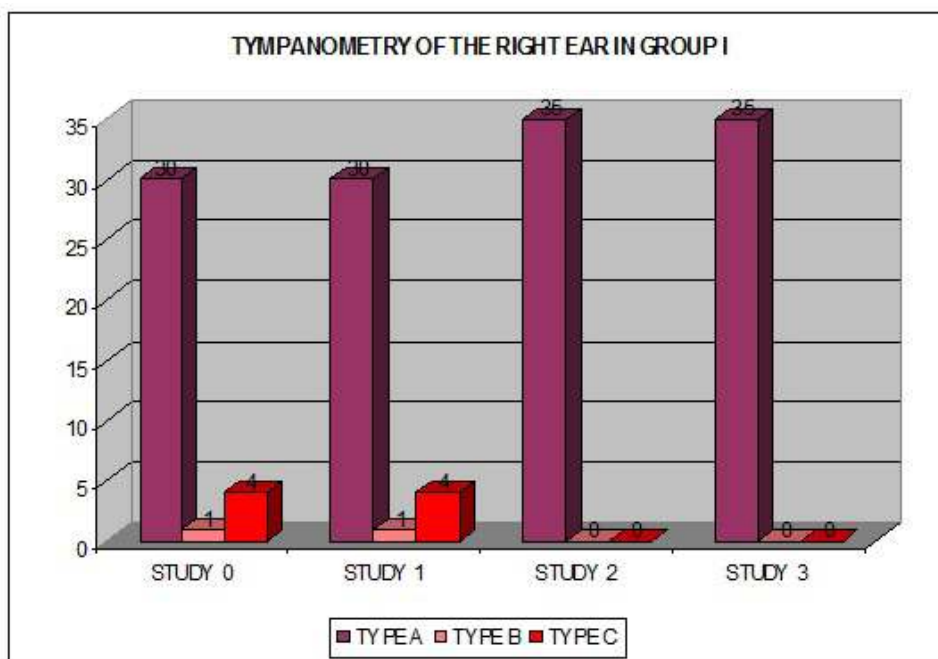


Fig. 1. Distribution of tympanometric curves of the right ear in group I in subsequent studies.

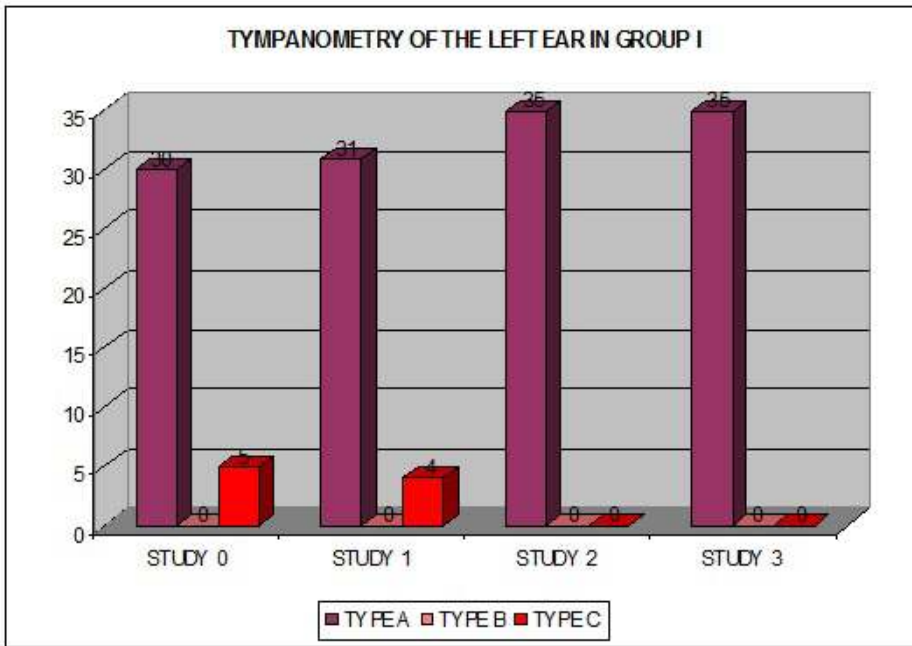


Fig. 2. Distribution of tympanometric curves of the left ear in group I in subsequent studies.

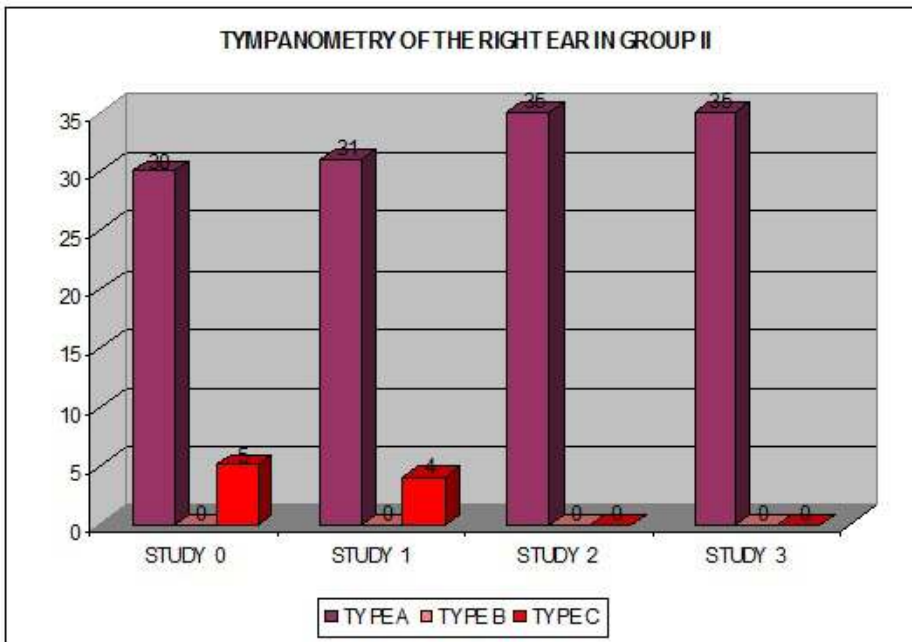


Fig. 3. Distribution of tympanometric curves of the right ear in group II in subsequent studies.

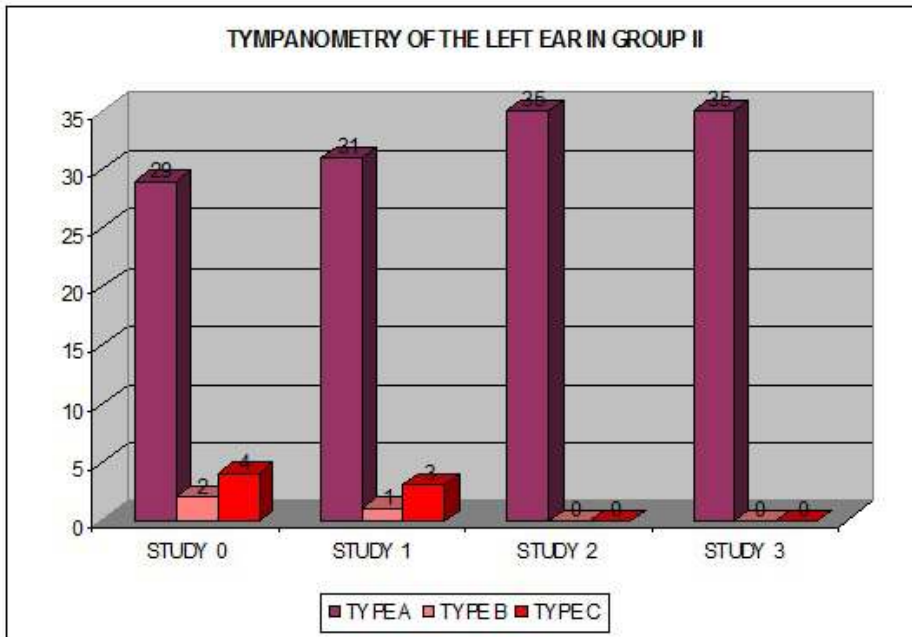


Fig. 4. Distribution of tympanometric curves of the left ear in group II in subsequent studies.

No statistically significant ($p < 0.001$) impaired patency of the Eustachian tubes was observed after the conchoplasty surgeries, either by cryoablation or radioablation. Almost all patients had normal tympanometry test charts in preoperative and postoperative examinations (Fig. 5). Only individual patients had a transient disruption of the Eustachian tube patency, which resolved in the second week of postoperative follow-up (Fig. 6). Only one patient had already been diagnosed with chronic Eustachian tube dysfunction before cryoablation.

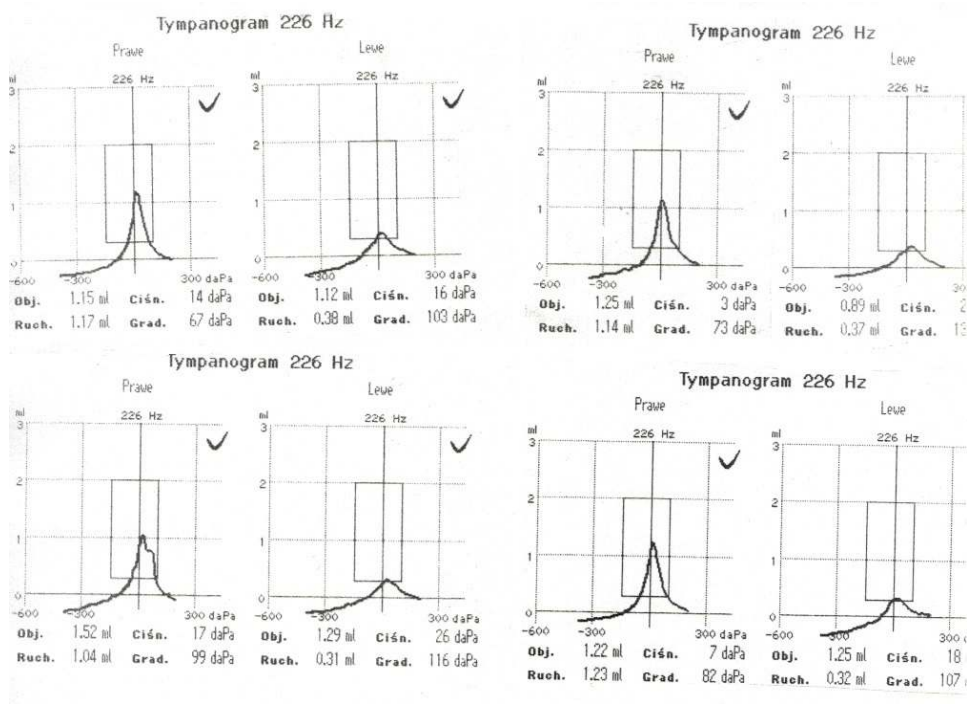


Fig. 5. Type A tympanogram.

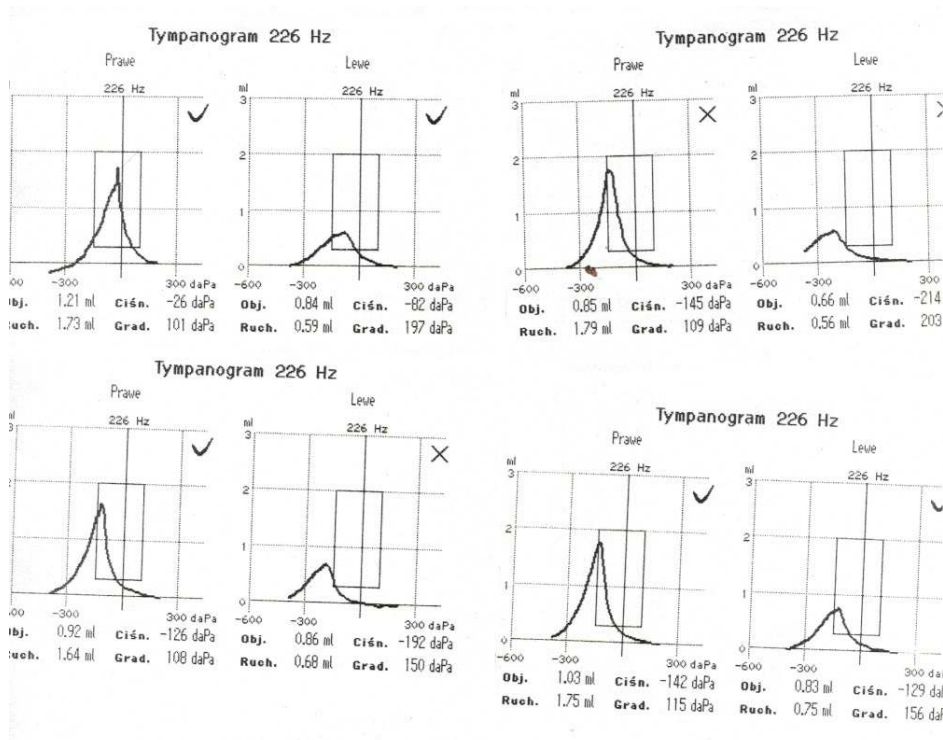


Fig. 6. Temporary impairment of patency of the left Eustachian tube.

DISCUSSION

The results obtained are extremely valuable from a clinical point of view. In the era of widespread passenger air transportation, patients quite often expect their doctor to precisely define their indisposition to fly on an airplane after rhinological surgery.

In their study, Otruin et al. showed that 6.1% of participants in passenger flights simulated in a hypobaric chamber were found to have obstructed Eustachian tubes manifested as “ear pain.” This symptom mainly affected people with allergic rhinitis or acute rhinitis [15]. In contrast, Jansen et al. showed significantly higher middle ear peak pressures and higher pressure differences after equilibration maneuvers in people with exposure of the Eustachian tube to increased atmospheric pressure [6,13]. Therefore, any patient who reports the symptom of a “plugged ear” should have a tympanometry test. Although there have been attempts to assess the patency of the Eustachian tube by other methods, like using CT scans of the temporal bones [11], undoubtedly tympanometry is the simplest, minimally invasive, safe and, above all, objective testing method.

Impedance audiometry has been used in hearing examinations for more than 70 years and is now one of the primary tools for objective diagnosis of the middle ear. The assessment of the middle ear's condition based on the tympanogram is made using various qualitative and

quantitative criteria. The qualitative criteria are based on the classification of tympanogram shapes (type A, B or C curve) [4,14,19,27,28]. When diagnosed with chronic inflammation of the Eustachian tubes, treatment is difficult. A recently promoted method of Eustachian tube balloonoplasty yielded positive results [18].

Salvinelli et al. evaluated the effects of rhinological surgery on the Eustachian tube and middle ear ventilation. Forty patients undergoing surgery showed no significant difference in tympanometric values despite the fact that the majority (95%) of patients reported a feeling of “full ear” after surgery (25%, $P < 0.001$) [22].

Similar results to ours were obtained by Harju et al. This researcher published in 2018 a randomized trial performed on 72 adult patients diagnosed with chronic hypertrophic rhinitis who underwent radiofrequency and diode laser ablation or sham surgery. The evaluations were conducted before and 3 months after surgery. The improvement in symptoms associated with Eustachian tube dysfunction following surgery on the anterior half of the inferior nasal turbinate has been shown to be equal to placebo [3].

Cryo- and radioablation of the inferior nasal turbinates is a simple medical procedure and, as our observations have shown, has no negative effect on middle ear physiology. Our ambition is to continue this research with additional groups of patients undergoing other rhinological surgeries, especially those that require the use of intranasal dressings. This is inspired, for example, by a clinical study by Bowles et al. of 57 patients, which found a high prevalence of concomitant symptoms of Eustachian tube dysfunction in patients with severe chronic sinusitis that improve after endoscopic sinus surgery. Tympanometric examinations were performed 3 and 9 months after endoscopic surgery [1].

CONCLUSIONS

1. Conchoplasties of the inferior nasal turbinates performed by cryo- and radioablation do not impair the patency of the Eustachian tubes.
2. After inferior nasal turbinate surgeries, the grace period for activities that particularly require unobstructed ear trumpets should be at least two weeks.

AUTHORS' DECLARATION

Study Design: Andrzej Wojdas, Roman Stablewski, Elżbieta Zgnilec. **Data Collection:** Andrzej Wojdas, Roman Stablewski, Elżbieta Zgnilec. **Manuscript Preparation:** Andrzej

Wojdas, Roman Stablewski, Elżbieta Zgnilec. The Authors declare that there is no conflict of interest.

REFERENCES

1. Bowles PF, Agrawal S, Salam MA. Eustachian Tube dysfunction in chronic rhinosinusitis: pre and post-operative results following endoscopic sinus surgery, a prospective study. *Rhinology*. 2019; 57(1): 73-77.
2. Eifan AO, Durham SR. Pathogenesis of rhinitis. *Clin Exp Allergy*. 2016; 46(9): 1139-51.
3. Harju T, Kivekäs I, Numminen J, et al. The effect of inferior turbinate surgery on ear symptoms. *Laryngoscope*. 2018; 128(3): 568-572.
4. Hoth S, Baljić I. Current audiological diagnostics. *GMS Curr Top Otorhinolaryngol Head Neck Surg*. 2017; 18: 16.
5. Ikeda R, Kikuchi T, Oshima H, et al. Diagnosis of the Patulous Eustachian Tube. *Ear. Nose Throat. J*. 2020; 13: 145561320925938.
6. Jansen S, Boor M, Meyer MF, et al. Influence of repetitive diving in freshwater on pressure equalization and Eustachian tube function in recreational scuba divers. *Diving Hyperb Med*. 2017; 47(4): 223-227.
7. Joshi KS, Ho VWQ, Smith ME, et al. The effect of topical xylometazoline on Eustachian tube function. *J. Laryngol. Otol*. 2020; 134(1): 29-33.
8. Jurkiewicz D, Bień D, Szczygielski K, et al. Clinical evaluation of balloon dilation eustachian tuboplasty in the eustachian tube dysfunction. *Eur Arch Otorhinolaryngol*. 2013; 270(3): 1157-60.
9. Juszczak HM, Loftus PA. Role of Allergy in Eustachian Tube Dysfunction. *Curr Allergy Asthma Rep*. 2020; 20(10): 54.
10. Kaya M, Dağlı E, Kırat S. Does Nasal Septal Deviation Affect the Eustachian Tube Function and Middle Ear Ventilation? *Turk Arch Otorhinolaryngol*. 2018; 56(2): 102-105.
11. Kourtidis S, Hempel JM, Saravakos P, et al. Diagnostic value of computed tomography in Eustachian tube dysfunction. *Auris Nasus Larynx*. 2021; 27: S0385-8146(21)00235-2.

12. Maniaci A, Lechien JR, La Mantia I, et al. Effectiveness of submucosal turbinoplasty in refractory obstructive rhinitis: a prospective comparative trial. *Eur. Arch. Otorhinolaryngol.* 2022; 25. doi: 10.1007/s00405-022-07267-0.
13. Meyer MF, Boor M, Jansen S, et al. Influence of repetitive diving in saltwater on pressure equalization and Eustachian tube function in recreational scuba divers. *Diving Hyperb Med.* 2017; 47(4): 214-215.
14. Namysłowski G, Fira R. Audiometria impedancyjna. In: Sliwinska-Kowalska M, ed. *Audiologia kliniczna.* Łódź: MEDITON. 2005; 137-49.
15. Ohruji N, Takeuchi A, Tong A, et al. Allergic rhinitis and ear pain in flight. *Ann Allergy Asthma Immunol.* 2005; 95(4): 350-353.
16. Paprocka-Zjawiona M, Nowosielska-Grygiel J, Kikowski Ł. Zastosowanie kriochirurgii w leczeniu alergicznych i niealergicznych nosa. *Wiad. Lek.* 2018; 71(6): 1135-1140.
17. Passali D, Loglisci M, Politi L. Managing turbinate hypertrophy: coblation vs. radiofrequency treatment. *Eur Arch Otorhinolaryngol.* 2016; 273(6): 1449-1453.
18. Plaza G, Navarro JJ, Alfaro J, et al. Consensus on treatment of obstructive Eustachian tube dysfunction with balloon Eustachian tuboplasty. *Acta Otorrinolaringol. Esp.* 2020; 71(3): 181-189.
19. Pruszewicz A, Obrębowski A. Audiometria impedancyjna. In: Pruszewicz A, ed. *Zarys Audiologii klinicznej.* Poznań: Wydawnictw Akademii Medycznej im. K. Marciniowskiego. 1994; 249-263.
20. Rohozinski TB. Zastosowanie chirurgii radiofalewej w leczeniu schorzeń laryngologicznych. *Magazyn Otolaryngologiczny.* 2010; 1(9): 31-34.
21. Rotenburg B, Busato GM, Agrawal SK. Endoscopic ligation of the patulous eustachian tube as treatment for autophony. *Laryngoscope.* 2013; 123(1): 239-243.
22. Salvinelli F, Casale M, Greco F, et al. Nasal surgery and eustachian tube function: effects on middle ear ventilation. *Clin Otolaryngol.* 2005; 30(5): 409-413.
23. Sato T, Kawase T, Yano H, et al. Trans-tympanic silicone plug insertion for chronic patulous Eustachian tube. *Acta Otolaryngol.* 2005; 125(11): 1158-1163.
24. Schröder S, Ebmeyer J. Diagnostik und Therapie von Funktionsstörungen der Tuba auditiva. *HNO.* 2018; 66(2): 155-166.
25. Sinno S, Mehta K, Lee ZH, et al. Inferior Turbinate Hypertrophy in Rhinoplasty: Systematic Review of Surgical Techniques. *Plast. Reconstr. Surg.* 2016; 138(3): 419e-429e.

26. Stölzel K, Bandelier M, Szczepek AJ. Effects of surgical treatment of hypertrophic turbinates on the nasal obstruction and the quality of life. *Am J Otolaryngol.* 2017; 38(6): 668-672.
27. Śliwa L, Kochanek K. Nowe metody audiometrii impedancyjnej. Część I. Tympanometria wieloczęstotliwościowa (wielokomponentowa). *Now Audiofonol,* 2016; 5(3): 9–21
28. Śliwa L, Kochanek K. Nowe metody audiometrii impedancyjnej. Część II. Szerokopasmowa tympanometria reflektancyjna. *Now Audiofonol,* 2016; 5(4): 11-23.
29. Takano A, Takahashi H, Hatachi K, et al. Ligation of eustachian tube for intractable patulous eustachian tube: preliminary report. *Eur Arch Otorhinolaryngol.* 2007; 264(4): 353-357.
30. Ungureanu R, Sarafoleanu D. Quality of life in patients with chronic hypertrophic rhinitis after CO2 laser turbinoplasty. *Romanian Journal of Rhinology.* 2012; 2(8): 209-216.
31. Verkest V, Pingnet L, Fransen E, et al. Piezo-assisted Turbinoplasty Versus Partial Turbinectomy in External Septorhinoplasty: A Prospective Comparative Study in 100 Patients. *Aesthetic Plast Surg.* 2022, doi: 10.1007/s00266-021-02662-0.
32. Zielińska-Bliźniewska H, Olszewski J. The Use of Crysurgery in Otolaryngology. Crysurgery and Colposcopy. In: Practices, outcomes and potential complications. 2016; 1: 3-15.