

OWN EXPERIENCES IN THE APPLICATION OF INTRAOPERATIVE 3D SPATIAL IMAGING IN THE ENDOSCOPIC SURGERY OF THE PARANASAL SINUSES

Andrzej WOJDAS¹, Roman STABLEWSKI¹

¹ Department of Otolaryngology, Military Institute of Aviation Medicine, Warsaw, Poland

Source of support: Own sources

Author's address: A. Wojdas, Military Institute of Aviation Medicine, Krasińskiego Street 54/56, 01-755 Warsaw, e-mail: awojdas@wiml.waw.pl

Introduction: Intraoperative spatial imaging using a high-resolution 3D camera is a state-of-the-art technique applied to endoscopic paranasal sinus surgery. It enables better visualization of the surgical site, improves depth perception and facilitates tissue identification. All 3D endoscopy capabilities are still under review.

The purpose of this study is to compare analogous endoscopic surgeries performed with 3D technique and those performed with traditional 2D technique based on the analysis of length of surgery, blood loss, occurrence of intraoperative complications and hospital stay time.

Material: The material included 346 patients who underwent endoscopic paranasal sinus surgery with unilateral or bilateral sinus opening. In case of 152 patients, corrective surgery of the nasal septum was additionally performed. The patients were divided into two groups (2D group and 3D group) comprising 173 patients each, who underwent paranasal sinus opening using 2D and 3D endoscopic visualization. Each group was divided into four subgroups: the first were patients after bilateral paranasal sinus surgery (PSS), the second were patients after bilateral endoscopic paranasal sinus surgery and nasal septal correction surgery (PSS+NS), the third were patients after unilateral paranasal sinus surgery (UPSS), and the fourth group was patients after unilateral endoscopic paranasal sinus surgery and nasal septum correction surgery (UPSS+NS).

Methods: The surgery was carried out using a TipCam 3D endoscope from Storz (Germany), 18 mm in length, 4 mm in diameter, with 30° optics, with an integrated camera capable of

transmitting 3D images, as well as classic 2D endoscopes, 16 mm in length, 4 mm in diameter and 30° optics, along with a video track and instrument set.

Patients underwent unilateral or bilateral endoscopic surgery with opening of the maxillary sinuses, frontal sinuses, anterior and posterior ethmoid as well as corrective surgery of the nasal septum.

Patients underwent unilateral or bilateral endoscopic surgery with opening of the maxillary sinuses, frontal sinuses, anterior and posterior ethmoid as well as corrective surgery of the nasal septum.

Results: The length of surgery were as follows in the 2D group: 2D/PSS+NS group — 107 min. (± 22); 2D/PSS group — 95 min (± 24); 2D/UPSS+NS group — 68 min (± 21); 2D/UPSS group — 53 min (± 14);

The length of surgery in the 3D group: 3D/PSS+NS group — 91 min. (± 17); 3D/PSS group — 83 min (± 20); 3D/UPSS+NS group — 69 min (± 15); 2D/UPSS group — 49 min (± 10);

Among the complications were early and late postoperative bleeding, eyelid or orbital hematomas, and eyelid edema. There were 17 complications in the 2D group (9.82%), and 7 complications in the 3D group (4.05%).

Conclusions: It was found that 3D endoscopic surgeries significantly reduced the length of surgery, especially in serious bilateral paranasal sinus surgeries. and influenced a decrease in perioperative complications.

3D endoscopic surgeries had no significant effect on the amount of blood loss and the length of the patient's stay at the Clinic.

Keywords: intraoperative 3D spatial imaging, endoscopic paranasal sinus surgery, chronic rhinosinusitis

INTRODUCTION

The treatment of choice for chronic rhinosinusitis that does not respond to conservative treatment is surgical treatment in the form of Functional Endoscopic Sinus Surgery (*FESS*) [2,3].

At the heart of endoscopic surgery was *Messenklinger's* [9] 1969 clarification of the role of mucociliary transport in the upper respiratory tract and the sinus cavity oropharyngeal complex.

The first functional endoscopic sinus surgeries were performed in the 1970s. The precursors of this surgical method were *Stammberger* [15] and *Lund* [8] in Europe and *Kennedy* [5] and *Kern* [6] in the US. In Poland, endoscopic surgery in the treatment of chronic sinusitis was initiated by *Krzeski* [7] in 1993.

The idea behind these surgeries is to restore normal anatomical conditions (drainage and ventilation of the sinuses), safely remove the diseased tissue under visual control, and preserve intact anatomical structures that are not affected by the disease process from an intranasal access, without the need for external cuts of the skin and mucosa.

The last two decades have seen a real technical revolution in endoscopic surgery. In the second decade of the 21st century, the novel technology of three-dimensional endoscopy was introduced [14].

Intraoperative 3D spatial imaging with a high-resolution camera is the latest technique used in endoscopic sinus surgery. It enables better visualization of the surgical site, improves depth perception and facilitates tissue identification. All 3D endoscopy capabilities are still under review.

The purpose of this paper is to compare endoscopic surgeries performed using 3D technique and those performed using traditional 2D technique based on the analysis of the length of surgery, blood loss during the procedure, occurrence of intraoperative complications and the length of patient's hospital stay.

MATERIAL

The material included 346 patients who underwent endoscopic paranasal sinus surgery with unilateral or bilateral paranasal sinus opening for chronic unilateral or bilateral rhinosinusitis. The surgeries included at least the opening of the anterior and posterior ethmoid, frontal and maxillary sinuses. In case of 152 patients, corrective surgery of the nasal septum was additionally performed. The patients were divided into two groups (2D group and 3D group) comprising 173 patients each, who underwent paranasal sinus opening using 2D and 3D endoscopic visualization. Each group was divided into four subgroups: the first was made up of patients who underwent bilateral paranasal sinus surgery (PSS) — 66 patients, the second was made up of patients who underwent bilateral endoscopic paranasal sinus surgery and nasal septal correction surgery (PSS+NS) — 54 patients, the third was made up of patients who underwent unilateral paranasal sinus surgery (UPSS) — 31 patients, and the

fourth was made up of patients who underwent unilateral endoscopic paranasal sinus surgery and nasal septal correction surgery (UPSS+NS) — 22 patients.

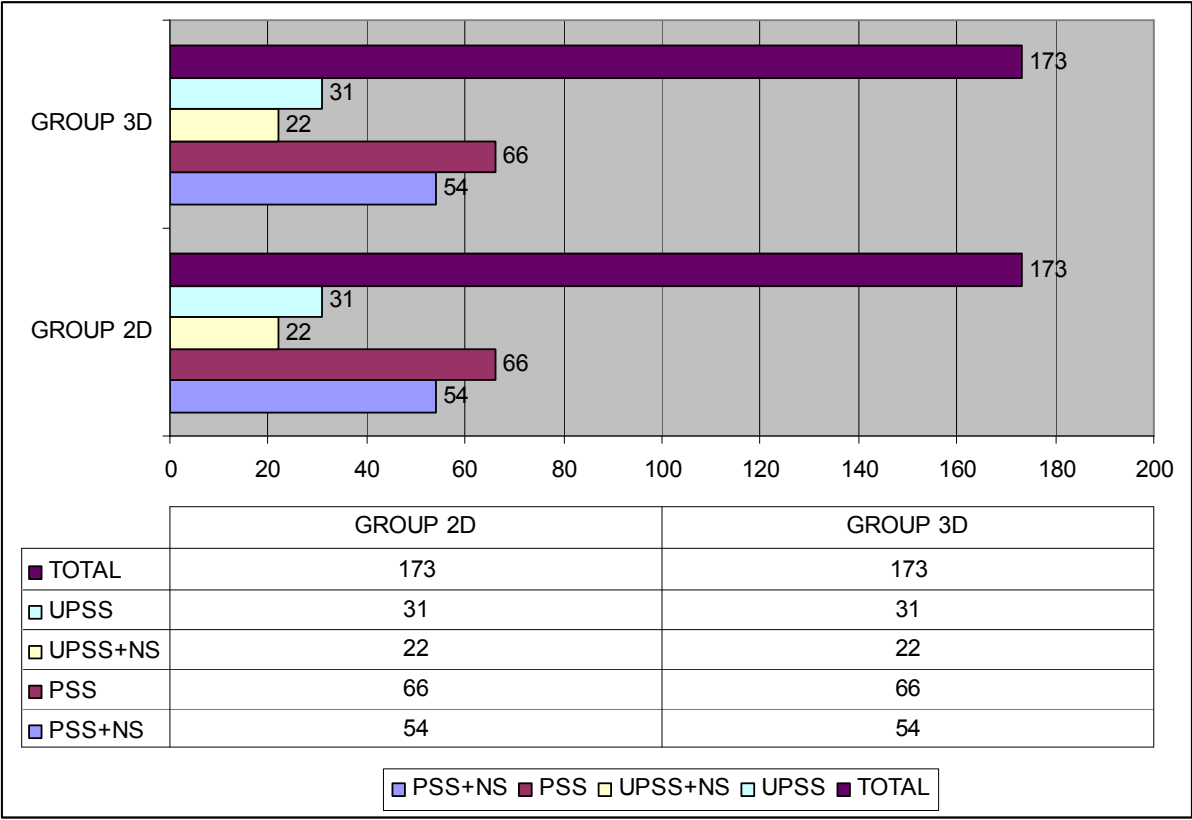


Fig.1. Group division.

METHODS

The surgery was carried out using a *TipCam 3D* endoscope from *Storz* (Germany), 18 mm in length, 4 mm in diameter, with 30° optics, with an integrated camera capable of transmitting 3D images, as well as classic 2D endoscopes, 16 mm in length, 4 mm in diameter and 30° optics, along with a video track and instrument set.

Patients underwent unilateral or bilateral endoscopic surgery with opening of the maxillary sinuses, frontal sinuses, anterior and posterior ethmoid as well as corrective surgery of the nasal septum.

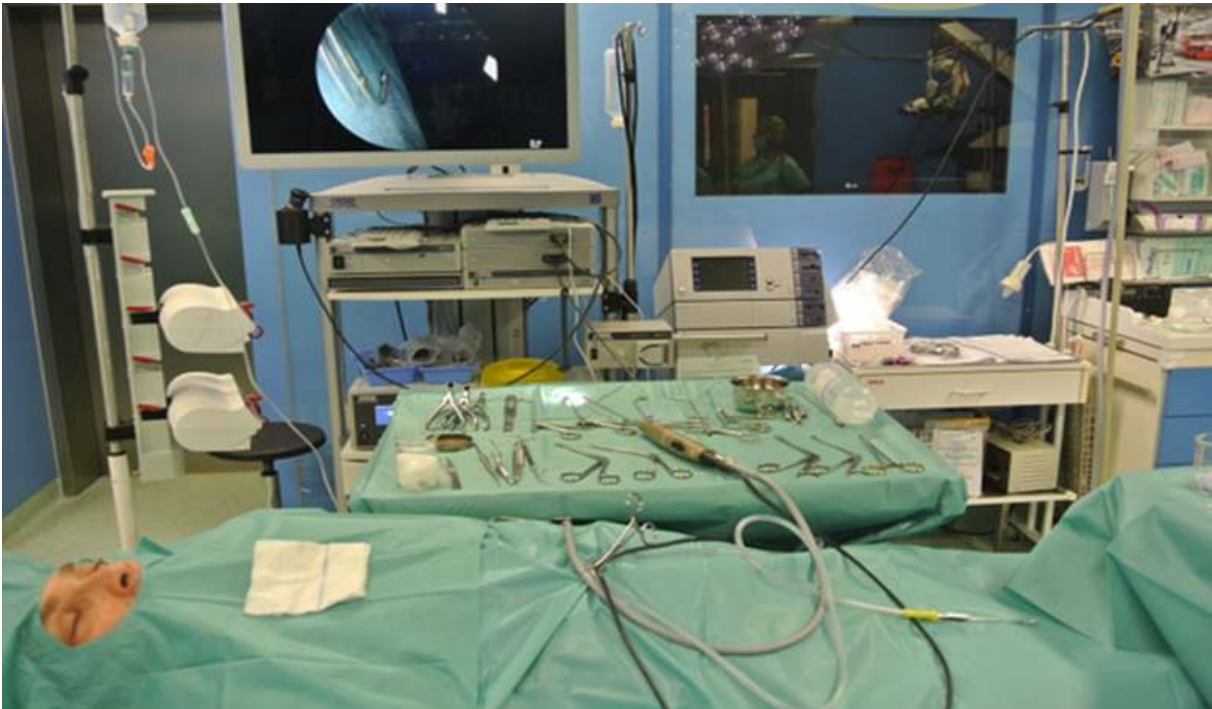

Fig. 2. Endoscopic set with 3D video track.

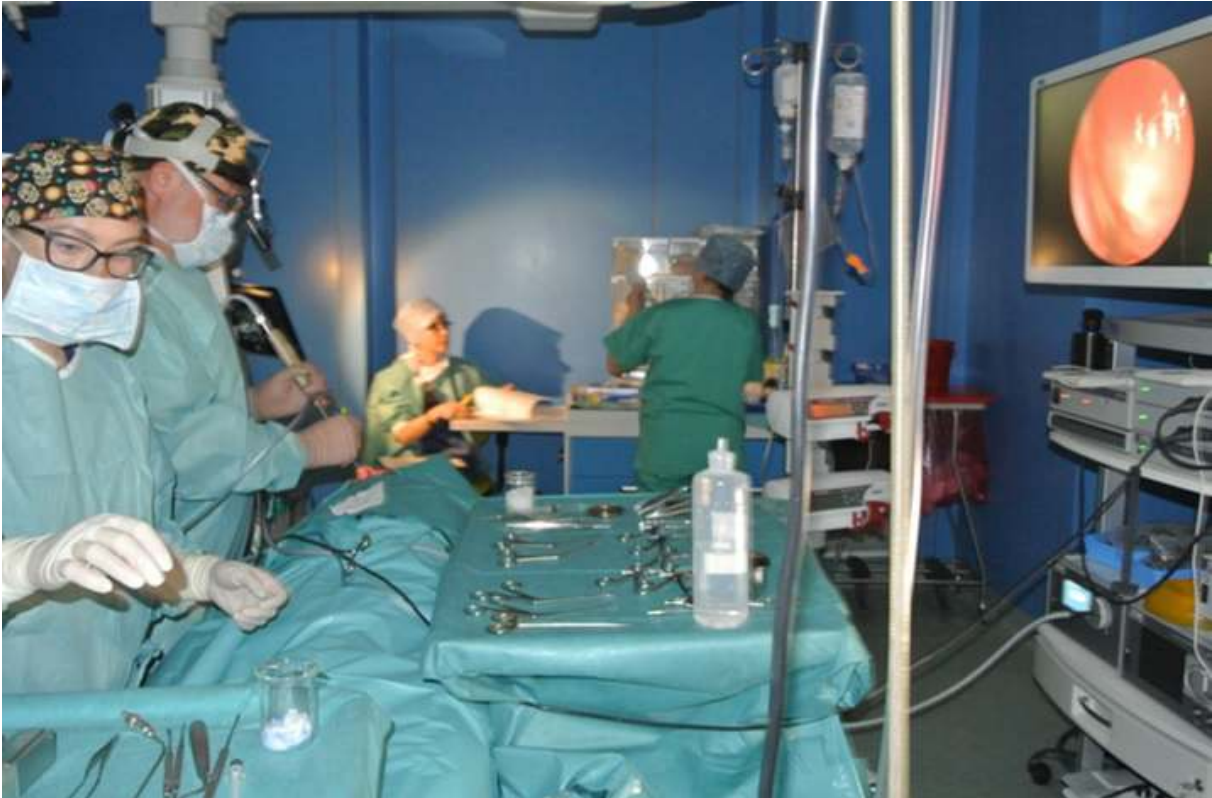

Fig. 3. Endoscopic surgery performed using 3D technology.

RESULTS

The length of surgery in the 2D group: 2D/PSS+NS group — 107 min. (± 22); 2D/PSS group — 95 min (± 24); 2D/UPSS+NS group — 68 min (± 21); 2D/UPSS group — 53 min (± 14);

The length of surgery in the 3D group: 3D/PSS+NS group — 91 min. (± 17); 3D/PSS group — 83 min (± 20); 3D/UPSS+NS group — 69 min (± 15); 2D/UPSS group — 49 min (± 10) (Table 1).

Tab. 1. Average surgery length in each patient group.

	2D	3D
PSS+NS	107 MIN (± 22)	91 MIN (± 17) 85%
PSS	95 MIN (± 24)	83 MIN (± 20) 88%
UPSS+NS	68 MIN (± 21)	69 MIN (± 15) 10,1%
UPSS	53 MIN (± 14)	49 MIN (± 10) 92%

There was a statistically significant reduction in surgery length in bilateral paranasal sinus surgery and bilateral surgery with nasal septal correction when 3D optics were used.

Among the complications were early and late postoperative bleeding, eyelid or orbital hematomas, and eyelid edema. There were 17 complications in the 2D group (9.82%), and 7 complications (4.05%) in the 3D group (Table 2).

Tab. 2. A set of complications in each patient group.

	2D	3D
EARLY BLEEDING	4 (2,31%)	2 (1,16%)
LATE BLEEDING	2 (1,15%)	0
HAEMATOMA OF THE EYELIDS OR ORBIT	7 (4,05%)	3 (1,73%)
SWELLING OF THE EYELIDS	4 (2,31%)	2 (1,16%)
TOTAL	17 (9,82%)	7 (4,05%)

The volumes of blood loss in each group are shown in Table 3. The average length of patient's hospital stay is presented in Table 4.

Tab. 3. Average blood loss in ml in surgeries performed.

	2D	3D
PSS+NS	420 (± 180) ML 100%	400 (± 160) ML 95%
PSS	450 (± 150) ML 100%	380 (± 140) ML 92%
UPSS+NS	300 (± 100) ML 100%	280 (± 80) ML 93%
UPSS	270 (± 150) ML 100%	250 (± 100) ML 92%

Tab. 4. Average length of patient stay at the Clinic.

	2D	3D
AVERAGE LENGTH OF HOSPITAL STAY (DAYS)	3,98	3,97

DISCUSSION

The duration of endoscopic sinus surgery is affected by numerous factors, ranging from bleeding in the surgical site to the skill of the operator. All surgeries reviewed were performed by the same medical team, in the same operating room and under similar physical conditions. There was a statistically significant reduction in surgery length for bilateral paranasal sinus surgeries, especially in bilateral surgeries with nasal septal correction when the average surgery length was shorter by up to fifteen minutes (± 20).

Our data on the duration of endoscopic paranasal sinus surgery differ from studies presented by *Tomazic et al.* [16], who found that the lengths of surgeries using 2D and 3D endoscopy were similar. They even opined that 2D techniques provide better results in terms of feasibility for routine endoscopic approaches. In contrast, *Nassimizadeh et al.* [10] observed in their study that comparable 3D surgeries take less time than 2D surgeries.

The most common complications include bleeding requiring blood transfusion, fluid leak, loss of smell, orbital hematoma, meningitis, transient and permanent double vision, and intracranial bleeding. The number of complications after FESS surgery decreases as the surgeon becomes more skilled and experienced in using this surgical technique [3].

According to an assessment by *Ogino-Nashimura et al.* [12] the length of surgery and bleeding volumes in 3D and 2D endoscopic surgeries are comparable.

In a paper by *Seredyk-Burduk et al.* [13] based on material including 1,658 patients who underwent FESS surgery performed using 2D technique, complications occurred in 0.66% of patients.

Complications arising after endoscopic surgery in our study account for a much higher percentage of patients. It was 9.82% in the 2D group and 4.05% in the 3D group, and included intraoperative and postoperative bleeding, eyelid and orbital hematomas, and eyelid edema. Early bleeding was stopped during the surgeries performed. Late bleeding required revision surgery. We treated eyelid and orbital hematoma and eyelid edema in traditional manner, and in all patients the symptoms resolved without permanent ocular dysfunction. We managed to avoid all the so-called serious and very serious complications, which include: visual disturbances, lacrimation, nasal fluid leak, etc. As reported by *Hadelmann et al.* [4], the rate of such complications ranges from 0.36% to 3.1%.

The values of blood loss during surgery in ml and the average length of the patient's hospital stay were similar in 2D and 3D endoscopic surgery. Similar results, analyzing the literature, were found by *Zaldi et al.* [17]. They report that complication rates, surgery length, and length of hospital stay were the same for 2D and endoscopic surgery. However, all studies have shown that subjective depth perception and spatial orientation have improved significantly with 3D technology. Otorhinolaryngologists felt that 3D endoscopy improved the identification of key anatomical structures and was superior to 2D endoscopy in these respects [1,14].

Undoubtedly, the near future of endoscopic paranasal sinus surgery will be associated with 3D endoscopy, which is currently at the beginning of its development [11].

CONCLUSIONS

Comparing endoscopic paranasal sinus surgeries performed using 2D and 3D techniques and summarizing the results obtained, we obtained the following conclusions:

1. It was found that 3D endoscopic surgeries significantly reduced the length of surgery, especially in serious bilateral paranasal sinus surgeries. and influenced a decrease in perioperative complications.
2. 3D endoscopic surgery has had a significant impact on the decrease in perioperative complications.
3. 3D endoscopic surgeries had no significant effect on the amount of blood loss and the length of the patients stay at the Clinic.

AUTHORS' DECLARATION

Study Design: Andrzej Wojdas, Roman Stablewski. **Data Collection:** Andrzej Wojdas, Roman Stablewski. **Manuscript Preparation:** Andrzej Wojdas, Roman Stablewski. The Authors declare that there is no conflict of interest.

REFERENCES

1. Albrecht T, Baumann I, Plinkert PK, Simon C, Sertel S. Three-dimensional endoscopic visualization in functional endoscopic sinus surgery. *Eur Arch Otorhinolaryngol.* 2016; 273(11): 3753-3758. doi: 10.1007/s00405-016-4040-3.
2. Fokkens WJ, Lund VJ, Hopkins C, Hellings PW, Kern R, Reitsma S. et al. European position paper on rhinosinusitis and nasal polyps. *Rhinology.* 2020; 58:1–464.
3. Golusiński W, Januszewski J. Diagnostyka i leczenie przewlekłego zapalenia nosa i zatok przynosowych. *Postępy w chirurgii głowy i szyi.* 2006; 1: 46–52.
4. Halderman AA, Sindwani R, Woodard TD. Hemorrhagic Complications of Endoscopic Sinus Surgery. *Otolaryngol Clin North Am.* 2015; 48(5): 783-93.
5. Kennedy DW. Prognostic factors, outcomes and staging in ethmoid sinus surgery. *Laryngoscope.* 1992; 102: 1-18.
6. Kern EB, Sinusitis. *J. Allerg. Clin. Immunol.* 1984; 73(1): 25-31.
7. Krzeski A. Endoskopowa operacja zatok przynosowych. *Otolaryngol. Pol.* 1994; 48 Suppl 17: 83-91.
8. Lund VJ, Holmstron M, Scadding GK. Functional endoscopis sinus surgery in the management of chronic rhinosinusitis. An objective assessment. *J. Laryngol. Otol.* 1991; 105: 832-5.
9. Messerklinger W. Die normalen Sekretwege in der Nase des Menschen. *Arch. Klin. Exp Ohren-Nasen-Kehlkopfheilkd.* 1969; 195: 138-151.

10. Nassimizadeh A, Lancer H, Hodson J, Ahmed S. Three-Dimensional Endoscopic Endonasal Surgery: A Systematic Review; *Laryngoscope*. 2022; 132(10): 1895-1903.
11. Nassimizadeh A, Zaidi SM, Nassimizadeh M, Kholief A, Ahmed SK. Endoscopic training-is the future three-dimensional? *Laryngoscope Investig Otolaryngol*. 2018; 3(5): 345-348.
12. Ogino-Nishimura E, Nakagawa T, Sakamoto T, Ito J. Efficacy of three-dimensional endoscopy in endonasal surgery. *Auris Nasus Larynx*. 2015; 42(3): 203-207.
13. Seredyka-Burduk M, Burduk PK, Wierzchowska M, Kaluzny B, Malukiewicz G. Ophthalmic complications of endoscopic sinus surgery. *Braz. J. Otorhinolaryngol*. 2017; 83(3): 318-323.
14. Singh A, Saraiya R. Three-dimensional endoscopy in sinus surgery. *Curr. Opin. Otolaryngol. Head Neck Surg*. 2013; 21(1): 3-10.
15. Stammberger H. Endoscopic endonasal surgery — new concepts in treatment recurring sinusitis. Part I — Anatomical and pathophysiological considerations. *Otolaryngol. Head Neck Surg*. 1986; 4: 143-147.
16. Tomazic PV, Sommer F, Treccosti A, Briner HR, Leunig A. 3D endoscopy shows enhanced anatomical details and depth perception vs 2D: a multicentre study. *Eur Arch Otorhinolaryngol*. 2021; 278(7): 2321-2326.
17. Zaidi HA, Zehri A, Smith TR, Nakaji P, Laws ER. Efficacy of Three-Dimensional Endoscopy for Ventral Skull Base Pathology: A Systematic Review of the Literature. *World Neurosurg*. 2016; 86: 419-431.