



SPONTANEOUS RETROPHARYNGEAL HEMATOMA: CASE REPORT

Agnieszka WITKOWSKA-JANIK¹, Roman STABLEWSKI¹, Andrzej WOJDAS¹

¹ Department of Otolaryngology, Military Institute of Aviation Medicine, Warsaw, Poland

Source of support: The study was funded as a part of the research tasks (statutory research) of the Military Institute of Aviation Medicine in Warsaw.

Author's address: A. Witkowska, Military Institute of Aviation Medicine, Krasynskiego 54/56 Street, 01-755 Warsaw, e-mail: awitkowska@wiml.waw.pl

Introduction: Retropharyngeal space hematoma is a rare condition that may cause compression of the trachea and esophagus, as well as anterior displacement of the trachea, ultimately posing a risk of acute respiratory failure. The symptoms are often accompanied by subcutaneous hemorrhages on the neck and thorax. It is most often associated with injury to the cervical spine, head, or large vessels. The incidence of hematoma without an identifiable cause (spontaneous) is exceptionally rare and may complicate the diagnostic process.

Case report: A 57-year-old man was transferred from the Emergency Department of another hospital for emergency ENT consultation with a suspected neck phlegmon. Anamnesis included: a 4-day history of fever, increasing difficulty in swallowing, and cough. Three days prior to the hospitalization — there was an episode of severe coughing, sore throat, and progressive increase in the neck circumference. After verification of inflammatory parameters and imaging tests, a retropharyngeal hematoma was diagnosed and conservative treatment was implemented, in the form of antibiotic therapy and intravenous corticosteroid therapy, along with treatment to prevent vascular bleeding. Clinical improvement and gradual resorption of the hematoma were achieved.

Conclusions: The case presented here adds to the increasing number of literature reports concerning retropharyngeal hematomas. Increased clinical vigilance is warranted in patients reporting sudden dysphagia, odynophagia, and dysphonia. Quickly performing imaging tests and properly securing airway patency demonstrate key importance in the management of patients with this condition.

Keywords: retropharyngeal hematoma, hemorrhage, neck injury, parapharyngeal space hematoma, tracheostomy

Cite this article: Witkowska-Janik A, Stablewski R, Wojdas A: Spontaneous Retropharyngeal Hematoma: Case Report. Pol J Aviat Med Bioeng Psychol 2025; 31(3): 24-30. DOI: 10.13174/pjambp.29.05.2026.03

Copyright: © Military Institute of Aviation Medicine, 54/56 Krasynskiego St., 01-755 Warsaw, Poland • **License:** CC BY-NC 4.0 • **Indexation:** Ministry of Science and Higher Education (Poland) • **Full-text PDF:** <http://www.pjambp.com>

INTRODUCTION

Retropharyngeal hematoma is a rarely diagnosed condition, manifesting with compression of the trachea and the esophagus, anterior displacement of the trachea, and developing subcutaneous hemorrhages in the anterior aspect of the neck and thorax [4]. Most reported cases are associated with injuries to the cervical spine, head, or large vessels [2]. Nevertheless, cases of spontaneous retropharyngeal hematomas have also been reported, which occur much less frequently; consequently, in the absence of a history of trauma, establishing the correct diagnosis may pose a significant diagnostic challenge [18]. We report a case of spontaneous retropharyngeal hematoma in a patient following an upper respiratory tract infection.

CASE REPORT

Patient information

A fifty-seven-year-old man was transferred from another facility for emergency ENT consultation, with a diagnosis of neck phlegmon. He had a history of increasing difficulty in swallowing, cough, and fever for four days, and for the previous three days, following a coughing episode, an increasing sore throat and gradual enlargement of the neck circumference had been observed. The patient had a history of metabolic syndrome, including arterial hypertension, type 2 diabetes mellitus, class I obesity, gout, and dyslipidemia. The patient denied alcohol consumption and tobacco use, the intake of anticoagulants, as well as any neck or chest trauma preceding the onset of symptoms.

Diagnostic tests and their results

During hospitalization at the Department of Otolaryngology of the Military Institute of Aviation Medicine, standard diagnostic work-up for neck phlegmon was performed. Physical examination demonstrated that the patient was in good general condition, with no signs of crepitation on palpation of the thickened neck tissues, no dyspnea, and no clinical signs of inflammation or skin redness. Blood pressure was 150/90 mmHg, arterial oxygen saturation was 94% on room air, and body temperature was 36.5°C. In addition, the physical examination showed restricted neck range of motion: flexion to 40°, extension to 30°, and lateral flexion in both directions to 20°.

Initial laboratory test results were as follows: white blood cell count 5,240/ μ L, platelet count 325,000/ μ L, hemoglobin 13.2 g/dL, hematocrit

45%, erythrocyte sedimentation rate (ESR) 5 mm/h, and C-reactive protein (CRP) level of 33 mg/L. Arterial blood gas values were: pH 7.440, pO_2 76.7 mmHg, pCO_2 37.8 mmHg and HCO_3^- 25.5 mEq/L. Coagulation times were normal.

The inflammatory marker levels did not increase in subsequent measurements: white blood cell count 4,910/ μ L, 4,090/ μ L, and CRP 34.9 mg/L, 19.2 mg/L. Fiberscope examination showed hematoma on the posterior wall of the pharynx, extending from the area of the oropharynx to the hypopharynx. The hematoma did not involve the glottic level of the larynx — therefore, no decision was made to perform a tracheostomy (Fig. 1.).

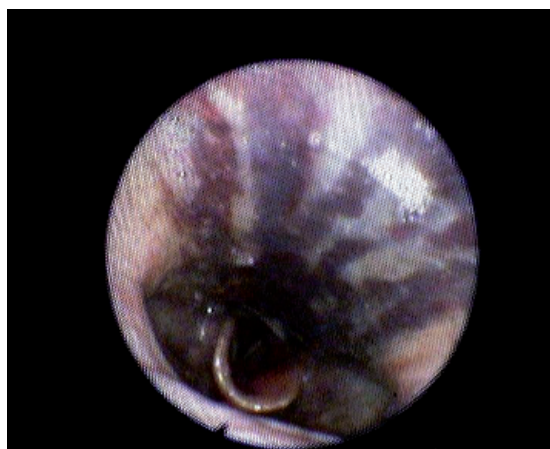


Fig. 1. Fiberscopic examination of the hypopharynx and larynx on the day of admission.

On contrast-enhanced computed tomography (CT) of the neck from the referring facility (Fig. 2.), suspected phlegmon was reported, with massive infiltration of the carotid vessel space on the left, with a wall thickness of up to 20 mm in the infrahyoid section. Secondary to this, there was displacement of the esophagus, trachea, and larynx to the right side, and displacement of the carotid vessels to the left side, without narrowing the larynx. The same infiltrate involved the left thyroid lobe anteriorly, caused dilation of the left part of the visceral space of the infrahyoid neck, with its penetration and spread into the retropharyngeal space, both in the infrahyoid and suprahyoid sections. An inflammatory reaction was also visible in the subcutaneous adipose tissue and under the deep cervical fascia, from the suprasternal region up to the left submandibular gland level. Densification of adipose tissue in the left vascular space at the level of lymph node groups IIa and IIb was also reported, with numerous, non-enlarged nodes of these groups. The overall imaging findings suggested an extensive phlegmon of the

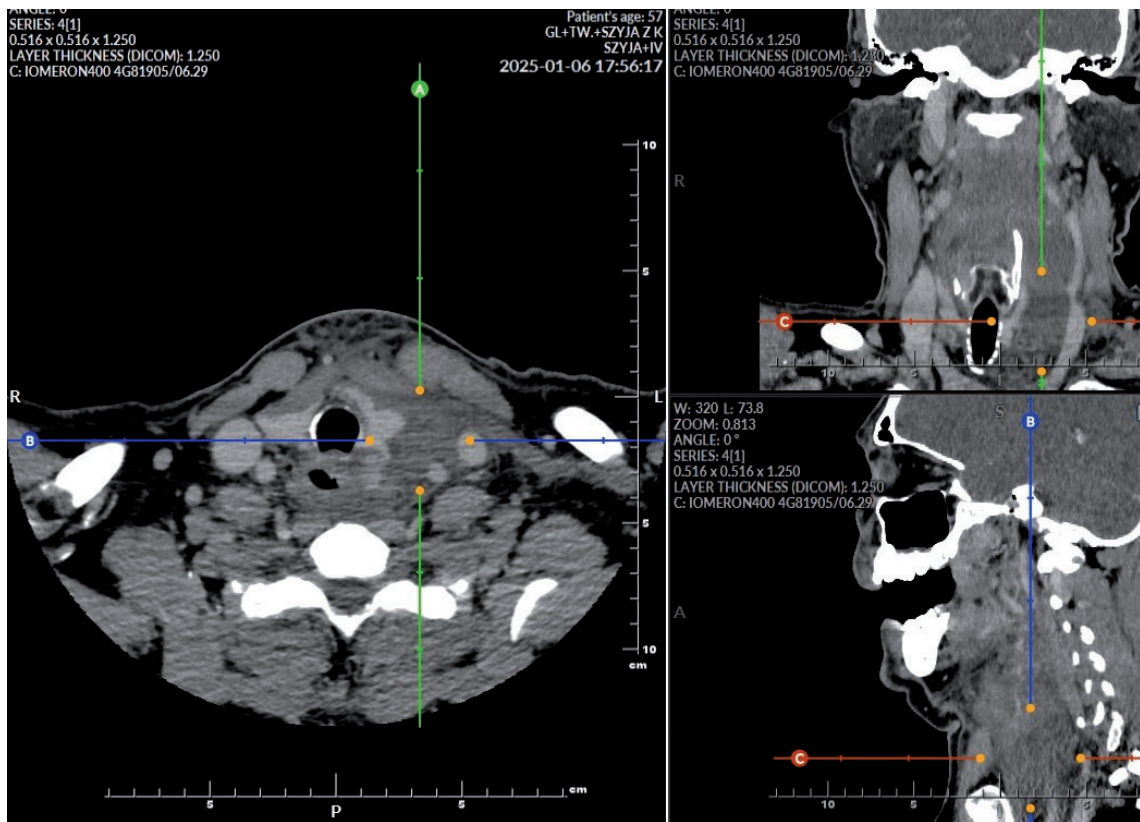


Fig. 2. Contrast-enhanced CT scan of the neck performed on the day of admission.

cervical spaces and of the retropharyngeal space on the left side. Dorsally to the left of the thyroid lobe and on the left side of the esophagus, a non-characteristic focal lesion 18 mm in diameter was visualized, with blurred borders, significantly enhancing after contrast administration, with no relation to the larynx, esophagus, trachea, or thyroid gland — suggesting a site of active bleeding, most likely venous in nature.

Course of hospitalization

Based on the foregoing, retropharyngeal hematoma was diagnosed and conservative treatment was implemented in the form of intravenous antibiotic therapy (metronidazole at 500 mg three times daily and ceftriaxone at 1 g twice daily); anti-edema treatment (dexamethasone at 8 mg once daily) and hemostatic treatment (tranexamic acid at 500 mg three times daily and etamsylate at 250 mg twice daily). Clinical improvement and gradual reduction and resorption of the hematoma were achieved.

Three days after the admission, an ecchymosis was observed on the anterior surface of the thorax (Fig. 3). A follow-up contrast-enhanced CT scan of the neck was performed, demonstrating thickening of the soft tissues with accompanying fluid bands within the retropharyngeal space at the level of the oropharynx and hypopharynx, both

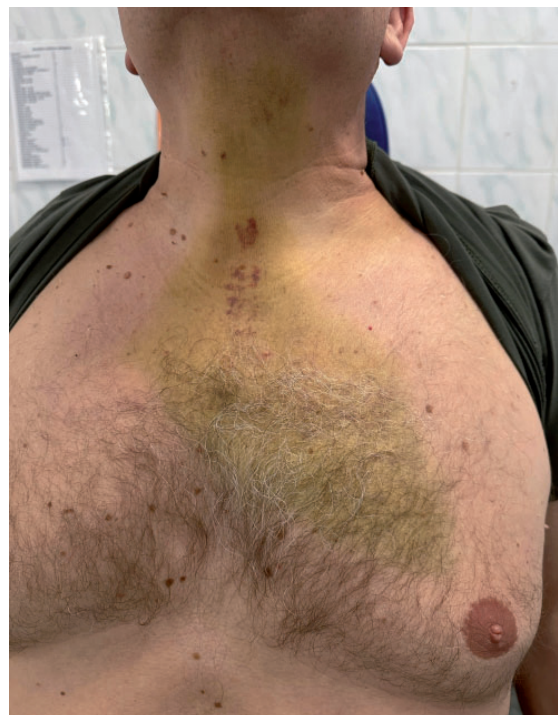

Fig. 3. Hematoma on the anterior surface of the thorax 3 days after the admission.

epiglottic valleculae and the left piriform recess compressed, with the right piriform recess also narrowed. Additionally, spread of the infiltrate along the carotid vessels was noted, posterior

to the left thyroid lobe, lateral to the esophagus, into the upper mediastinum, with circumferential thickening of the esophageal wall. Within the infiltrate, small nodular areas of enhancement after contrast administration were visible. There was slit-like glottic lumen, and narrowed laryngeal lumen at the supraglottic level. Compared with the previous examination, partial regression of the lesions was observed: edematous changes in the visceral space of the neck, in the infrahyoid area, and anterior to the left thyroid lobe were clearly reduced, with less thickening of the retropharyngeal space. An inflammatory reaction was found in the subcutaneous adipose tissue beneath the deep cervical fascia, in the subcutaneous tissue of the upper and anterior thoracic wall.

Condition at discharge

The patient was discharged after 5 days in good general condition with recommendations regarding observation and further treatment. He was advised to continue oral antibiotic therapy and hemostatic treatment for the next 9 days. A follow-up visit at the Otolaryngology Outpatient Clinic was scheduled 10 days later, together with contrast-enhanced magnetic resonance imaging (MRI) of the neck.

The MRI performed showed no abnormal fluid collections or any traces of previous bleeding within the soft tissues of the neck. No lesions were visualized in the retropharyngeal space. The structures of the pharynx, larynx, and parapharyngeal space were unchanged. The pharyngeal mucosa appeared smoothly outlined, the salivary glands were of normal size, with no visible focal lesions. Unevenly thickened mucosa of the esophagus included in the examination was noted.

DISCUSSION

Spontaneous retropharyngeal hematoma is exceedingly rare. Diffuse bleeding into the retropharyngeal space is an exceptionally rare cause of non-inflammatory neck edema and upper airway obstruction, and may be of either traumatic or non-traumatic etiology. The retropharyngeal space is an area containing loose connective tissue and retropharyngeal lymph nodes [1]. It is limited anteriorly by the buccopharyngeal fascia, which surrounds the pharynx, trachea, esophagus, and thyroid gland; posteriorly by the alar fascia; and laterally by the carotid vessel sheaths and the parapharyngeal spaces. It is the largest and probably one of the most important interfascial spaces of the neck, constituting a potential

channel infection spread to the mediastinum; it also allows the accumulation and enlargement of hematomas. The pretracheal, parapharyngeal, and retropharyngeal spaces are interconnected and also communicate with the subcutaneous spaces of the neck, which allows blood or infection to spread between them. Death may occur as a result of the rapid development of respiratory failure caused by upper airway obstruction, induced by bleeding within the sublingual, retropharyngeal, and parapharyngeal spaces [10].

The classic clinical picture is described as Capps' triad [4], which includes: compression of the trachea and esophagus, anterior displacement of the trachea along with subcutaneous hemorrhages on the neck and the anterior surface of the thorax.

Most reported cases of bleeding into the retropharyngeal space have occurred after trauma, specifically with cervical spine injuries. According to Patel et al. [16], the prevertebral space is widened in 60% of patients with neck trauma. Traumatic retropharyngeal hematomas predominantly occur after fractures of the cervical vertebrae, usually above the C6 level [22]. In one study, the most frequently coexisting injuries associated with retropharyngeal hematoma included fractures of the skull, ribs, long bones, and mandible, thoracic aortic dissection, lung contusion, brachial plexus injury, and cranial nerve VI palsy [23].

Other causes include coagulation disorders (anticoagulant therapy or hemorrhagic diatheses), rupture of the carotid artery and of a parathyroid adenoma, bleeding from periesophageal veins, infections, neoplastic metastases, angiographic procedures, foreign body ingestion, or sudden changes in pressure (for example, during vomiting, coughing, sneezing, or the Valsalva maneuver) [3]. In the case described, the most likely cause was rupture of a thyroid vein due to increased pressure following a coughing event.

Fiberoptic examination through the nasal cavity may reveal pharyngeal posterior wall bulging. Patients in unstable condition, with dyspnea and hypoxemia, require immediate evaluation and consideration of intubation in order to secure airway patency. Computed tomography of the neck and mediastinum is the diagnostic test of choice, allowing assessment of the extent of the hematoma and its relationship with other anatomical structures of the neck [20].

However, retropharyngeal hematoma is usually difficult to diagnose due to its rarity and the lack of characteristic clinical symptoms and diagnostic laboratory tests in most patients [8]. The patient may initially report only a sore throat, without

symptoms of dyspnea, which leads to misdiagnosed viral pharyngitis [9]. On clinical examination, the following are present: tenderness, edema, or subcutaneous hemorrhages within the neck. A lateral X-ray scan of the cervical spine is helpful in visualizing thickened prevertebral soft tissues, while a thoracic X-ray scan shows widened mediastinum in cases of an extensive hematoma [5]. Symptoms of an enlarging hematoma depend on its size and the mass effect. Odynophagia may be the first symptom, suggesting other, more probable diagnoses. However, as the hematoma enlarges, additional symptoms develop, such as neck pain and stiffness, dyspnea, dysphonia, dysphagia, drooling, and stridor, which ultimately lead to acute, life-threatening airway obstruction requiring urgent surgical intervention.

Patients with retropharyngeal hematoma have a relatively good prognosis, and cases of death are rarely reported [7]. Treatment depends on the location, size, and clinical course of the disease [16]. In the case of small hematomas, without symptoms of dyspnea, close observation is sufficient. The time to complete resorption of spontaneous hematomas reported in the literature is variable and ranges from 2 to 4 weeks [13]. In the case of enlarging hematomas, surgical treatment by drainage is recommended. When a hematoma develops as a consequence of anticoagulant overdose, vitamin K – or its combination with fresh frozen plasma, or with prothrombin complex concentrates – are used.

Compression of the upper mediastinum in more severe cases develops rapidly, and airway obstruction often occurs regardless of the bleeding cause [15]. In this context, it is important to determine whether the size of the retropharyngeal hematoma remains stable or is progressing, since this information is critical for assessing the risk of upper airway obstruction [17]. Death may occur as a result of the rapid respiratory failure development, caused by airway obstruction or compression of large vessels by bleeding within the sublingual, retropharyngeal, and parapharyngeal spaces [5].

Under such circumstances, when the trachea is displaced by the hematoma along with coexisting edema, endotracheal intubation may carry a significant risk, including the possibility of tracheal rupture [14]. Surgical treatment with hematoma drainage is occasionally necessary, especially when it is very extensive or hinders the conduct of mechanical ventilation. Likewise, performing a tracheostomy is technically difficult, and each of these procedures carries a risk of increasing the bleeding within the neck. The need to secure the

airway should be considered individually in each case; nevertheless, retropharyngeal hematoma causes airway obstruction in only 1.2% of patients [12]. In the spontaneous bleeding described in this paper, the clinical picture was relatively mild and self-limiting, without significant compression of the mediastinum. In this case, surgical treatment was not necessary.

Late complications include lack of hematoma resorption or formation of an abscess. There are no clear literature recommendations regarding the use of steroids or prophylactic antibiotic therapy in patients with retropharyngeal hematoma [3].

Differential diagnosis

The differential diagnosis of retropharyngeal hematoma includes retropharyngeal tendinitis and retropharyngeal space infection. Retropharyngeal tendinitis is caused by the deposition of calcium in the tendons of the longus colli muscle (Latin: *musculus longus colli*). On radiological imaging, an irregular calcified structure located in front of the C1 vertebra is typically found, with accompanying edema of the prevertebral (or retropharyngeal) soft tissues from C1 to C4 [11]. The clinical picture is characterized by sudden onset of severe neck and throat pain, aggravating with swallowing and head movements; this may be accompanied by mild fever and a slight ESR increase. The pain peaks within 2–5 days and then gradually subsides, usually resolving completely within 1–2 weeks. In the case described, initial clinical and radiological examinations ruled out this diagnosis.

The clinical symptoms of retropharyngeal space infection include acute or subacute onset of neck pain, dysphagia or odynophagia, an elevated white blood cell count, and low-grade fever. ESR may be slightly elevated, and the medical history often includes recent upper respiratory tract infection or minor head or neck trauma [9]. Possible other differential diagnoses include: lymphoma, laryngocele, cyst, emphysema, carcinoma, and abscess.

CONCLUSIONS

An accurate diagnosis of retropharyngeal hematoma is the key to a good prognosis. The first step in management is securing airway patency [21]. Conservative treatment with close patient monitoring should be the treatment of choice, although urgent surgical intervention occasionally becomes necessary [6]. Most hematomas undergo spontaneous regression within 2–4 weeks. It was not possible to identify the vessels that were the

source of the bleeding in the reported patient. The pharynx is supplied by branches of the external carotid artery, and cases of spontaneous rupture of the external carotid artery branches (for

example, the superior thyroid artery) have been reported in the literature [19]. We assumed that the case in question may have been related to these mechanisms.

AUTHORS' DECLARATION

Study design: Agnieszka Witkowska-Janik, Roman Stablewski, Andrzej Wojdas. **Collection of data:** Agnieszka Witkowska-Janik, Roman Stablewski, Andrzej Wojdas. **Manuscript preparation:** Agnieszka Witkowska-Janik, Roman Stablewski, Andrzej Wojdas. The Authors declare that they have no conflicts of interest.

CONSENT

Written, informed consent was obtained from the patient for publication of this case report and the accompanying illustrative materials. A copy of the written consent is available for review by the Editor-in-Chief of this journal.

REFERENCES

1. Abukhder, Munir, Jonathan Hulme, Shakira Nathoo, and Shubhi Shubhi. 2021. "Spontaneous Retropharyngeal Haematoma with Direct Oral Anticoagulant Medication." *BMJ Case Reports* 14 (5): e240369.
2. Alabdulqader AA, Almudawi NA, Alkhonezan SM, Almudawi MA, Alkhonezan MM, Alshehri GA, Alnatheer AM. Traumatic retropharyngeal hematoma: A systematic review of reported cases. *Saudi Medical Journal*. 2024 Jan;45(1):10.
3. Arredondo-Montero J. Cough-related spontaneous retropharyngeal emphysema in a pediatric patient with Influenza A infection: a case report. *Boletín médico del Hospital Infantil de México*. 2025 Aug;82(4):263-6.
4. Capps, Richard B. 1934a. "Multiple Parathyroid Tumors With Massive Mediastinal And Subcutaneous Hemorrhage" *The American Journal of the Medical Sciences* 188 (6): 800–804.
5. Chiti-Batelli, Sandro, F Vaz, and Scott Coman. 2005. "Traumatic Retropharyngeal Haematoma in an Anticoagulated Patient: Case Report and Proposal for a Clinical Protocol." *Acta Oto-Laryngologica* 125 (4): 443–45.
6. De La Torre L, Huang K, Angulo JE, Ramirez CA. Surgical Management of a Traumatic Retropharyngeal Hematoma in a Patient on Dual Antiplatelet Therapy: A Case Report. *Journal of Oral and Maxillofacial Surgery*. 2024 May 1;82(5):595-9.
7. Dedouit, Fabrice, Stéphane Grill, Céline Guilbeau-Frugier, Frédéric Savall, Daniel Rougé, and Norbert Telmon. 2014. "Retropharyngeal Hematoma Secondary to Cervical Spine Surgery: Report of One Fatal Case." *Journal of Forensic Sciences* 59 (5): 1427–31.
8. Du G, Bi Y, Li Y, Song L, Wang J. Conservative treatment of giant spontaneous retropharyngeal hematoma: A case report. *Medicine*. 2025 Dec 26;104(52):e46846.
9. Fox EC, Manchala V. Retropharyngeal Hematoma as an Unusual Presentation of Myelodysplastic Syndrome: A Case Report. *The American Journal of Case Reports*. 2018 Aug 17;19:969.
10. Hsu, Tun-Yen, Ting-Chou Tsai, Chuan-Chien Yang, Tzer-Zen Hwang, Chih-Chieh Tseng, and Chih-Chun Wang. 2008. "Near-Fatal Sore Throat." *The Lancet* 371 (9618): 1136.
11. Huynh K, Shi Y, Gritsenko K, Briendenbach K, Diaz S, Sterling F, Treki A, Shaparin N, Koushik S, Raghavan J, Lee K. Airway management in acute hematoma formation following anterior cervical spine surgery. *Orthopedic Reviews*. 2024 Oct 3;16:121402.
12. Kuhn, J. E., and G. P. Graziano. 1991. "Airway Compromise as a Result of Retropharyngeal Hematoma Following Cervical Spine Injury." *Journal of Spinal Disorders* 4 (3): 264–69.
13. Mallick J, Guillot M, Castelain V, Michaud A. Retropharyngeal haematoma with subtotal upper airway obstruction after puncture attempt: a case report. *Journal of International Medical Research*. 2024 Oct;52(10):03000605241281665.
14. O'Neill, J. V., J. M. Toomey, and G. G. Snyder. 1977. "Retropharyngeal Hematoma Secondary to Minor Blunt Trauma in the Elderly Patient." *The Journal of Otolaryngology* 6 (1): 43–46.
15. Oyedokun TO, Durr KM. Extensive upper airway hematoma secondary to supratherapeutic warfarin anticoagulation. *Clinical Practice and Cases in Emergency Medicine*. 2020 Oct 19;4(4):634.

16. Patel SV, Reza A, Rice SR. Mind the gap: life-threatening retropharyngeal haematoma resulting in acute airway obstruction following blunt trauma by closing train carriage doors. *BJR | case reports*. 2021 May 1;7(3):20200190.
17. Rogers AL, Burnett A, Eckard P, Farsi S, Gardner JR, Dornhoffer JL, Saadi RA. A Systematic Review of Case Reports of Spontaneous Retropharyngeal Hematoma. *Laryngoscope Investigative Otolaryngology*. 2025 Jun;10(3):e70162.
18. Srivastava, Seema, and Tarun Solanki. 2008. "Retropharyngeal Haematoma - an Unusual Bleeding Site in an Anticoagulated Patient: A Case Report." *Cases Journal* 1 (1): 294.
19. Stenner, Markus, Victor Helmstaedter, Elmar Spuentrup, Gero Quante, and Karl-Bernd Huettenbrink. 2010. "Cervical Hemorrhage Due to Spontaneous Rupture of the Superior Thyroid Artery: Case Report and Review of the Literature." *Head & Neck* 32 (9): 1277–81.
20. Sugiura G Takahashi H, Yoshihisa K, Satoshi N. Successful management of retropharyngeal hematoma by trans-arterial embolism without intubation. *International Journal of Emergency Medicine (Online)*. 2021 Dec 1;14(1).
21. Suzuki, Takashi, Hiroshi Imai, Masataka Uchino, et al. 2004. "Fatal Retropharyngeal Haematoma Secondary to Blunt Trauma." *Injury* 35 (10): 1059–63.
22. Tsai, Shih-Hung, Chin-Wang Hsu, and Shi-Jye Chu. 2008. "Traumatic Retropharyngeal Hematoma after a Minor Head Injury." *The Journal of Trauma* 64 (2): 539.
23. Tsao, Yu-Ling, Chien-Chin Hsu, and Kuo-Tai Chen. 2021. "Blunt Traumatic Retropharyngeal Hematoma with Respiratory Symptoms: A Systematic Review of Reported Cases." *Emergency Medicine International* 2021.